

Case Report

Battered Baby Syndrome: A Barbaric Act

¹Rajendra Singh, ²Yogesh Sharma, ³PN Mathur, ⁴Nimish Khatri

Abstract

Battered baby syndrome is a heinous crime and brutish act. Knowledge of such cases gives us the thought that we are still living in barbaric era. By the thought of such cases one gets goose bumps. The battered child refers to the child usually less than three years of age, though it may occur at any age, who suffers repeated non-accidental injuries, sometime fatal, caused through episodes of violence by a parent or guardian. Physicians have a duty and responsibility to the child to require a full evaluation of the problem and to guarantee that no expected repetition of trauma will be permitted to occur. Forensic expert also has an important role to play in uncovering the cases of battered baby syndrome. We present two incidences of battered baby syndrome aged 12 year and 5 year. The first was a male child who committed suicide by hanging after beaten repeatedly by her mother. The second case was a female child, admitted in our hospital pediatrics side beaten repeatedly by her father.

Key Words: Battered baby syndrome, Crime, Trauma, Suicide

Introduction:

Battered baby syndrome is a heinous crime and brutish act. Unfortunately it is crime which is successfully hidden by its perpetrators. Child battering is one of the least documented violations in the country, says the records.

The reasons are manifold. In India, much like the rest of Asia, children are expected to respect and obey authority figures such as teachers, guidance counselors and principals and not question their actions. Rebellion is perceived as a sign of a bad upbringing. This sensibility perpetuates a culture of abuse. [1]

Battered baby syndrome is also known as child abuse syndrome, Caffey's syndrome, shaken baby syndrome, non-accidental injury in childhood, and maltreatment syndrome.

A battered child is one who has received repetitive physical injuries as a result of non-accidental violence, produced by a parent or guardian.

It has been seen that eldest or youngest child is a victim as it might be as a result of pregnancy before marriage or unwanted child a result of failure of contraception or illegitimate child. Cases found more in low socioeconomic class group than higher class family where family disharmony, long standing emotional problems or financial problems are more likely.

Many parents have criminal records or psychiatric problems with the background suggesting, battering parents were 'battered children' themselves. In addition to physical injury, there may be non-accidental deprivation of nutrition, care and affection. [2, 3] They are brought to the doctor with vague history, narrated by the parents, for sustaining the injury like, fall from a stair, bed or a table or that the baby "bruises very easily". [4]

The classical features of syndrome are obvious discrepancy between the nature of the injuries and explanation offered by the parents, and delay between the injury, and medical attention which cannot be explained. The constant feature is repetition of injuries at different dates, often progressing from minor to more severe. A particular feature is the denial by the parent of any injury. [2, 5]

Case Reports:

Here we were presented two cases of Battered baby syndrome

Case One:

An autopsy of a 12 year old male child was conducted as a case of hanging with following findings:

Corresponding Author:

¹Resident Doctor,
Department of Forensic Medicine and Toxicology,
S. P. Medical College, Bikaner, Rajasthan
E-mail: rajkulhari11@gmail.com

²Assoc. Prof & HOD, Dept. of FMT,

³Prof & HOD, Dept. of FMT,
Jhalawar Medical College, Jhalawar, Rajasthan

⁴Resident Doctor, Dept. of Pediatrics,
JLN Medical College, Sewangi (Meghe),
Dist. Wardha, Maharashtra

DOR: 01.11.2014 DOA: 02.12.2014

DOI: 10.5958/0974-0848.2015.00024.X

- Rigor mortis well developed, post-mortem staining present on back & was fixed.
- Multiple abrasions and contusions were present on body at places in different stage of healing. (Fig.1)
- A shallow brown coloured parchment like ligature mark of size 17 cm x 4.0 cm – 2.5 cm was present over neck antero-laterally above the thyroid cartilage and was running obliquely, upward, laterally and backwards on both sides.
- It was disappearing in hair of back of neck on right side and on left side was up to left mastoid process.
- The ligature mark was 3cm below the left ear lobule and 7cm below right ear lobule. On dissection, the underlying tissue was white glistening. (Fig. 2)

The Police did not mention any injury in **fardsurathall & panchnama** submitted by them before post-mortem examination.

The Investigating Officer and father of deceased were called and shown the injuries present on body.

On interrogation with father of deceased, he conveyed that the child was beaten repeatedly by his mother by a wiper without any reason and in his absence.

The father told about mother that she regularly takes nitrazepam daily otherwise she could not sleep throughout night. She also takes alcohol off and on.

There is no history of smoking and any other intoxicating drugs. The mother's self-childhood history was not good. Her mother got separated from his father in her early age and she remained with her mother till marriage in a poor socioeconomic environment.

The father also told that he is having two other sons also but only eldest son was bitten by her mother. The father when asked why she had beaten the child, she always threatened that she would file a case of dowry against him.

After beating, the child was not going to school for 3-4 days but surprisingly none of teacher observed and asked the reason for not coming to school. The neighbors also knew it but they were afraid of reporting the matter to the police due to threaten by mother of deceased.

The father of deceased who is a class-IV in government service is living separately from family and wife has put a case of dowry against husband. During the period of separation she got love affairs with some other individual but this relationship does not appears to the cause of repeated beating as child was beaten before.

Fig.1: Contusions on Leg on Dissection

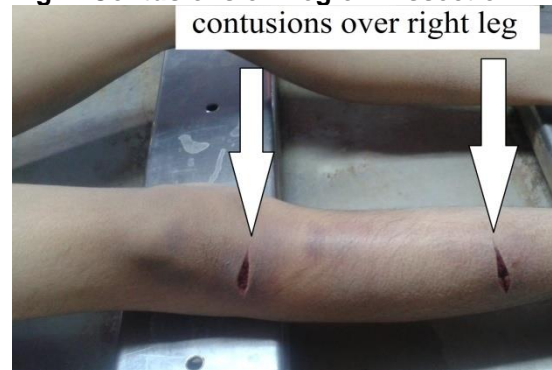
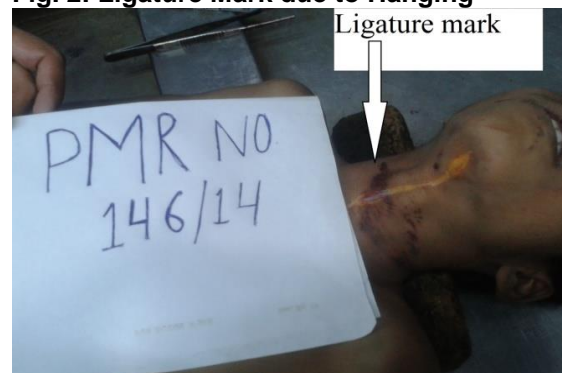
Fig. 2: Ligature Mark due to Hanging



Case Two:

A female child, 4 year old, was admitted in Department of pediatrics in our hospital by her mother; with chief complaints of swelling over left arm, multiple skin lesion and excessive crying since last 5 days. She had given history of infection on face, back and legs since 5 days and past history of trauma to arm due to fall from bed 12 days back.

On examination the child was poorly nourished. The temperature, pulse and respiration were normal. She was reluctant to move the left upper limb.

Firm, ill-defined tender swelling was present on proximal half of left arm. Multiple abrasions were present on both lower limbs, back of abdomen, both upper and lower limbs at places with brownish black scab & hypopigmented scars. (Fig. 3 & 4)

A bluish contusion of size 4cm x 3 cm was present on left buttock. The milestones were delayed. Blisters were present on sole of left foot and healed burn lesion on right ankle. (Fig. 5) Child was very irritable.

On investigation Hemoglobin was 4mg%. X-rays revealed fracture of shaft of upper third of left humerus. (Fig. 6)

On interrogation, mother of child was very reluctant to give an accurate account of the facts. She told that child fell from bed and having allergy to everything. When repeatedly

questioned, she confessed that the retrieval line had been pulled out by the father. On further probing she narrated that it was not an accidental fall from bed and allergy to anything. She told that she have three female child.

Fig. 3: Hypo-pigmented Scar on Forehead

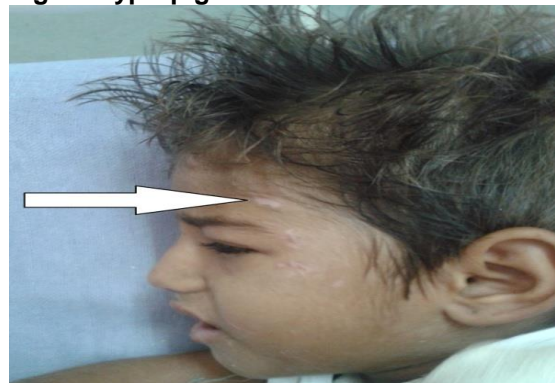


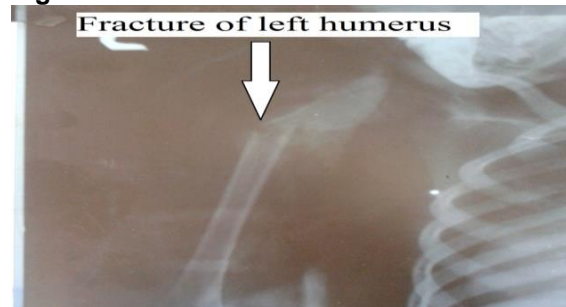
Fig. 4: Hypo-pigmented Scar & Abrasion

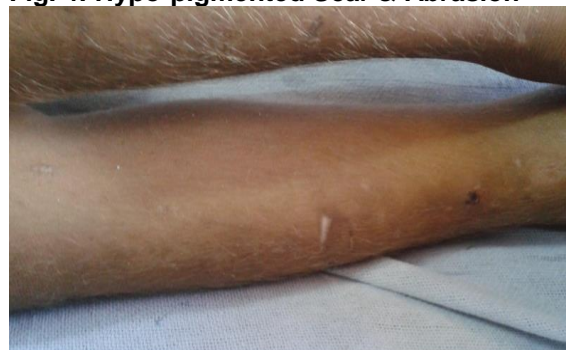

Fig. 5: Burn lesion by 'Cigarette burn'

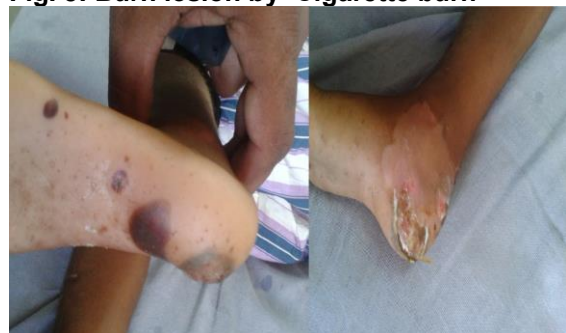

Fig. 6: Fracture of left Humerus



Both parents were illiterate & belong to lower socioeconomic family. Father takes alcohol daily. Because of female child, father was very much frustrated as they have already 2

female children in family before this. He used to beat her repeatedly by slapping and burn by cigarette towards this youngest one.

Discussion:

The case history of two children presented above illustrates some common features of the "battered baby syndrome." These are:

1. The discrepancy between the information offered by parents & clinical findings.
2. Both parents deny any physical abuse of the child.
3. Repetitive nature of the traumatic episodes.
4. One child of a family, commonly the eldest or the youngest & often unwanted.
5. Family belongs to poor socioeconomic status.
6. Alcohol and Drugs consumed in both cases.
7. Delay in seeking medical advice and treatment.
8. Unhappy childhood experiences in parents.
9. Child beaten by dominating person in family.
10. A particular type of cigarette burn present on sole. Such burns are most often seen over parts not normally covered by clothing. The mark may be rounded or bizarre in appearance. [6]
11. Discord between the parents & the marriage may be unstable.

Before diagnosing battered baby syndrome, we must have proper knowledge of some other pathological conditions in which long bones fractures occur with history of seemingly minor trauma. Even these kinds of fractures occur recurrently and show pathological changes similar to those of physical abuse, i.e. osteogenesis imperfecta, scurvy, congenital syphilis, spina bifida etc. In bleeding disorder, such as purpura, hemophilia etc., recurrent collection of blood may look like contusions. [3]

Before labeling a case as "battered baby syndrome" it should be thoroughly investigated and all the possibilities of accidental injury should be ruled out so as to avoid unnecessary harassment of an innocent. [7]

In a case of child abuse, a Multidisciplinary Team (MDT) is widely accepted and commonly used approach globally. This method unites all the agencies involved in managing the case of child abuse and facilitates their joint efforts towards the common goal of protecting children and convicting criminals.

Generally the different systems work more or less independently with little coordination with each other. Such an approach may cause emotional trauma to the child repeatedly at every stage – history narration,

treatment, investigation, prosecution and protection. An MDT approach makes such services less intrusive, more child sensitive and child friendly. [8]

In medical education, the specialties that should specifically deal with battered child syndrome are Pediatrics and Forensic Medicine. Searches of various Indian textbooks that are commonly used by students in various regions of the country show that most of them do not vividly cover the topic.

The textbooks that do mention it, do not have specific instructions as to what the doctor's or nurse's action should be, should they suspect battered child syndrome. Under such circumstances, the chance of child battering being reported to any authority is very slim.

It is rare that doctors take the trouble of reporting and insisting on the child's welfare in terms of changing custody and involving police and child welfare organizations. This leads to most cases of child abuse and violence go unreported. The absence of an official agency to look into specifically child abuse only aggravates this menace. [1]

Conclusions:

Doctor, who is approached for first-aid by the parents, must keep their eyes open. In the past the numbers of cases of battered baby syndrome were less, reason for it appears to be joint family. Nowadays there is misuse of dowry cases, as mentioned in first case. This has been already stated by honorable courts. Neighbor should be vigilant & they should report any such crime to police.

The school teachers should be vigilant. They always keep their eye open on student, who are not coming to school for seven days or more without prior information & they should asked the student, after taking in confidence for reason of absence from school. If child gives history of repeatedly beaten by parents, should be reported to police.

It has been found that poverty & alcohol abuse are two main devils that results in battered baby syndrome & measures should be taken for upliftment of socioeconomic status.

Because the cases we have reported are only two, it does not mean that such instances are rare in our country. These are just curtain raisers to a bigger tragic drama. Forensic expert has an important role to play in uncovering the cases of battered baby syndrome and gathering evidence for their successful prosecution.

References:

1. **Shailat V.** Perspectives on Child battering in India. American International Journal of Research in Humanities, Arts and Social Sciences 2013; P.154-156.
2. **Reddy K.S. N.** The Essentials of Forensic Medicine and Toxicology, 32nd ed, Medical Book Company; Hyderabad; 2013. P.424-426.
3. **Patel P.R, Vaghela D.** Battered baby syndrome: The extreme case. J Indian Acad. Forensic Med.2009; 31(2); P.147-150.
4. **Nandy A.** Nandy's Handbook of Forensic Medicine and Toxicology. 1st ed, New Central Book Agency (P) Ltd; Kolkata; 2013. P.359.
5. **Mathiharan K, Patnaik A K.** Modi's Medical Jurisprudence and Toxicology, 24th ed, Lexis Nexis; New Delhi; 2013. P.713-715.
6. **Vij Krishan.** Textbook of Forensic Medicine and Toxicology, Principle and Practice. 6th ed,Reed Elsevier India Pvt. Ltd; 2014 P.321-324.
7. **Prasanna J.S.** Battered child? – A case report. J Indian Acad. Forensic Med.2007; 29(4):1-3.
8. **Chaudhary V.** Battered Baby Syndrome- A Case Report, Medico-Legal Update 2012; 12(1):Pp.123-124.